# Deal with rebleeding BEFORE it occurs

THE VTI ENDOSCOPIC DOPPLER SYSTEM*

## A SOUND breakthrough in the management of acute peptic ulcer hemorrhage

- Easy and economical to use
- Does not require EUS equipment or training

*"After endoscopic therapy, I use the Doppler probe to determine adequacy of hemostasis by assessing for the presence or absence of subsurface blood flow."*

**– Richard C.K. Wong, MD,**
**Professor of Medicine,**
**Case Western Reserve University,**
**Cleveland, OH**

HEARING IS BELIEVING

VTI
Vascular Technology

VTI Endoscopic Doppler (E-DOP)

# The VTI Endoscopic Doppler System*

*"The members of the CURE GI Hemostasis Group and I have found the VTI endoscopic Doppler probe to be very useful for studies of arterial blood flow in lesions, and in the diagnosis, risk stratification, and treatment of patients with severe GI hemorrhage from focal lesions including peptic ulcers, Dieulafoy's lesions, diverticula, rectal ulcers & delayed post-polypectomy hemorrhage. Endoscopic Doppler has expanded our ability to accurately risk stratify patients and lesions beyond visual cues such as stigmata of hemorrhage by detection of underlying arterial blood flow before and after endoscopic treatments.*

*For endoscopic hemostasis, the Doppler probe has allowed us to provide focused treatment of the underlying artery because we can detect blood flow & location of the artery before treatment and confirm definitive endoscopic hemostasis and obliteration of the underlying arterial flow afterward by repeat Doppler examination. Our group is conducting prospective and randomized controlled studies which show promising results for the role of endoscopic Doppler in improving clinical outcomes of high risk patients with severe UGI & colon hemorrhage."*

**– Dennis M. Jensen, MD,**
**Professor of Medicine,**
**David Geffen School of Medicine at UCLA,**
**Los Angeles, CA**

An easy to use, economical tool, the VTI E-DOP allows endoscopists to identify vessels that cannot be located with visualization alone. **No EUS equipment or training is needed.** This compact system utilizes disposable Doppler probes which optimize patient safety and probe reliability. Available for upper GI or lower GI applications, the probes can be passed down a 2.8mm or larger channel.

**In acute peptic ulcer hemorrhage, E-DOP allows the endoscopist to:**

1. Map the arterial course within the ulcer base
2. Target hemostatic therapy appropriately
3. Identify patients at increased risk for rebleeding

## Published studies show the benefit of Doppler guided therapy in the treatment of acute peptic ulcer hemorrhage

- Doppler-guided endoscopic hemostasis of acute peptic ulcer hemorrhage results in significantly lower rates of recurrent bleeding. [1,2]
- Doppler positive ulcers have a significantly higher risk of recurrent bleeding than Doppler negative ulcers.[3,4]
- Ulcers that remain Doppler positive immediately after endoscopic therapy are at significantly higher risk for recurrent bleeding.[3,4]

Doppler examination of this submucosal gastric lesion demonstrates a prominent venous flow signal, allowing the endoscopist to confirm the diagnosis of gastric varices and rule out other submucosal pathologies.[5] Preliminary studies have also demonstrated the utility of the Doppler probe in the treatment of gastric varices using cyanoacrylate injection.[6] Other promising indications for use of E-DOP include endoscopic submucosal dissection , lower GI hemorrhage and needle knife endotherapy. [7-10]

# (E-DOP)

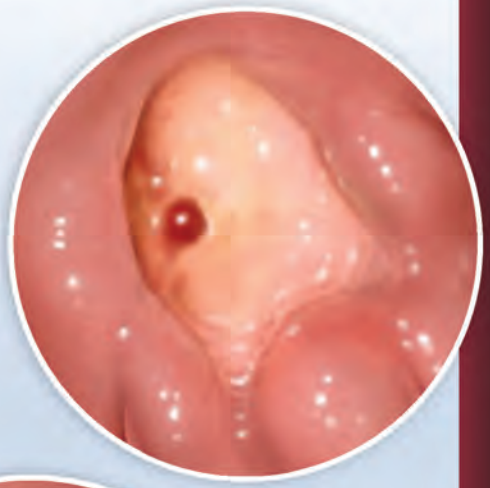

Endoscopic examination reveals an ulcer with a pigmented region at the 9 o'clock position. Studies have shown that while some endoscopists may classify this lesion as an ulcer with a nonbleeding visible vessel, others may classify it as an ulcer with a flat spot (poor/moderate interobserver agreement in the classification of stigmata of recent hemorrhage). In the former case, the ulcer would be treated endoscopically; in the latter, no endoscopic treatment would be administered.

Doppler examination of the ulcer reveals a strong arterial signal within this lesion. Use of the Doppler probe allows the endoscopist to map out the course of the underlying artery. The vessel can be "heard" just above the pigmented region, following a 9 o'clock to 1 o'clock course within the ulcer base. This "acoustic map" allows the endoscopist to target therapy appropriately.

Combination therapy including epinephrine injection and thermal coagulation have been used to treat this ulcer, with therapy focused in the region of the Doppler identified arterial signal. Doppler examination of the ulcer post therapy reveals that the ulcer is now Doppler negative. Arterial flow within the ulcer base has been adequately occluded.

*"I routinely use a Doppler probe to examine an ulcer where visual bleeding stigmata is uncertain; for instance, is it a NBVV requiring endoscopic therapy or a flat spot that does not? The Doppler probe provides an "acoustic map" of the subsurface artery that allows for targeted therapy."*

**– Richard C.K. Wong, MD, Professor of Medicine, Case Western Reserve University, Cleveland, OH**

Alternatively, the ulcer can be treated with the application of hemoclips. By using the "acoustic map" delineated by the Doppler probe, the endoscopist can accurately target the placement of the clips to insure that the artery is adequately occluded. Doppler examination of the ulcer post therapy reveals that the ulcer is in fact Doppler negative.

**Vascular Technology**

*US Pat. No. 8,206,304

Vascular Technology

WWW.VTI-ONLINE.COM
Toll Free: 1-800-550-0856
International: 603-594-9700

## ORDERING INFORMATION

| Catalog # | Description |
|---|---|
| 108720-AC | VTI 20 MHz Selectable Depth Doppler Transceiver |
| 108110-US | Hospital Grade Power Cord -- US |
| 108110-SUPPLY | Power Supply |
| 108670 | GI Endoscopic Style Doppler Probe, Sterile |
| 108690 | Colonoscopic Style Doppler Probe, Sterile |

References:
1. Kohler B, Maier M, Benz C, Riemann JF. Acute ulcer bleeding: a prospective randomized trial to compare Doppler and Forrest classifications in endoscopic diagnosis and therapy. Dig Dis Sci 1997;42:1370-4. 2. Jensen DM, Ohning GV, Kovacs TO, et al. Doppler ultrasound probe (DUP) as a guide to endoscopic hemostasis of ulcers with stigmata of recent hemorrhage (SRH). Gastrointest Endosc 2010;71:AB113. 3. Wong RCK. Endoscopic Doppler ultrasound probe for acute peptic ulcer hemorrhage. Gastrointest Endosc 2004;60:804-12. 4. Wong RCK, Chak A, Kobayashi K, et al. Role of Doppler US in acute peptic ulcer hemorrhage: Can it predict failure of endoscopic therapy? Gastrointest Endosc 2000;52:315-321. 5. Wong RC, Farooq FT, Chak A. Endoscopic Doppler US probe for the diagnosis of gastric varices (with videos). Gastrointest Endosc. 2007;65(3):491-6. 6. Salah W, Dumot JA. Through-The-Scope Doppler Ultrasound Guided Cyanoacrylate Injection: A New Technique for the Treatment of Gastric Variceal Hemorrhage. Gastrointest Endosc 2013;77:AB116(Sp621). 7. Uedo N, Takeuchi Y, Ishihara R, et al. Endoscopic Doppler US for the prevention of ulcer bleeding after endoscopic submucosal dissection for early gastric cancer: a preliminary study (with video). Gastrointestinal Endosc. 2010;72:444-448. 8. Jensen DM, Ohning GV, Kovacs TO, et al. Doppler Ultrasound Probe (DUP) for Risk Stratification and Endoscopic Hemostasis of Bleeding Colonic Lesions. Gastrointestinal Endosc. 2010;69:AB289. 9. Li Y, Shen B. Doppler ultrasound-guided endoscopic needle-knife treatment of an anastomotic stricture following subtotal colectomy. Endoscopy. 2011;43 Suppl 2 UCTN:E343. 10. Wu X-R, Wong RCK, Shen B. Endoscopic Needle-Knife Therapy for Ileal Pouch Sinus - A Novel Approach for the Surgical Complication. Gastrointest Endosc 2013 (in press).

030100-013 R3